

LETTERS

Botulinum toxin type B in blepharospasm and hemifacial spasm

Botulinum neurotoxins (BTXs) inhibit the presynaptic release of acetylcholine causing a chemical denervation that results in sustained muscle weakness and have been used in the past 20 years to induce selective blocking of hyperactive striatal (and smooth) muscles.¹ All the different seven serotypes of BTXs have in common the mechanism of action (block of the neuroexocytosis machinery inside the end plate, responsible for the release of acetylcholine into the neuromuscular junction), acting on different targets. The two commercially available serotypes, botulinum toxin type A and botulinum toxin type B (abbreviated BTX-A and BTX-B, respectively) are reported to act as zinc dependent endopeptidases on different intraneuronal target proteins.

The clinical value of BTX-A has been recognised for a long time and is widely demonstrated by hundreds of clinical reports. More recently a clinical usefulness of BTX-B has been investigated. Two controlled clinical trials have demonstrated that local intramuscular injections of BTX-B are effective in the treatment of cervical dystonia in patients with BTX-A responsive disease,² as well as in patients with BTX-A resistant disease (secondary non-responders).³ BTX-B was found to be effective in both studies, with a significant improvement observed in all the parameters investigated (severity, disability, and pain); action was found to last as long as 16 weeks.^{2,3}

Based on these favourable results, we investigated BTX-B treatment in blepharospasm (BLS), another common form of focal dystonia, and in hemifacial spasm (HFS). Indeed, despite BTX-A being an efficacious treatment for these conditions,⁴ a percentage of patients still shows a suboptimal response, particularly in long term treatments. They could, therefore, benefit from the availability of another botulinum toxin serotype.

Blepharospasm

We studied 13 subjects (10 women and 3 men; mean (SD) age at onset 51.5 (15.0) years; mean disease duration 9.1 (8.1) years) with BLS. BLS was diagnosed as idiopathic focal dystonia in 12 patients, and as tardive dystonia in one case. All patients had received BTX-A before, with a moderate to good response. Patients were excluded if they had received a BTX-A injection in the past three months for their BLS. After an informed consent was obtained, four pretarsal injections were placed around each eye; the fixed total dose for each treatment was 2500 units (0.8 ml of a solution obtained by adding 0.3 ml of saline to 0.5 ml of the commercially available BTX-B solution). Before each treatment, patients were assessed with an objective rating scale for dystonia (Burke-Fahn-Marsden scale, severity factors, items for BLS⁵); efficacy was assessed at the time of the peak effect (7-14 days after treatment) with the same rating scale and with a visual analogue scale assessment (Patient Global Assessment of Change), in which improvement was subjectively measured from 0% to 100%. Latency of the effect was defined as the time between the treatment and the first detectable clinical effect. Duration of effect was defined as the time between the first detectable clinical effect

Table 1 Response to BTX-B injections

	BLS		HFS	
	Before	After	Before	After
Latency to response (days)		3.0 (2.5)		3.7 (6.01)
Duration of response (days)		63.0 (17.5)		46.5 (22.1)
Objective rating scale (points)	1.9 (0.4)	1.1 (0.6)*	1.9 (0.8)	0.5 (0.5)*
Subjective visual analogue scale (%)		35.1 (28.5)		59.8 (26.9)

Results are expressed as mean (SD). *Student's *t* test between before and after injection: $p < 0.001$.

and the moment when that any benefit has completely worn off, both as reported by the patient. Each patient received a single treatment. Additionally, a telephone call was made to the patient each week to assess safety and duration of the effect.

Results of the trial are reported in table 1. Overall five patients rated the efficacy of BTX-B as superior to BTX-A and preferred to continue treatment with BTX-B. The drug was generally well tolerated, with the most common adverse effect of BTX-B being pain during the injection, which was reported by 11 of 13 of the patients. Other common side effects of BTX-A treatment, such as ptosis and epiphora, were mild and transient. One patient experienced an anaphylactic reaction, consisting of Quincke's oedema, from day two after the injection, though this resolved after treatment with corticosteroids.

Hemifacial spasm

We studied 11 subjects (six men and five women; mean age at onset 64.9 (10.4) years; mean disease duration 5.4 (3.9) years) with primary HFS. All patients had received BTX-A before, with a moderate to good response. Patients were excluded if they had received a BTX-A injection in the past three months for their HFS. After an informed consent was obtained, four pretarsal injections were placed around each eye, and two around the mouth; the fixed total dose of BTX-B for each treatment was 937.5 units. This was obtained taking 0.3 ml of the previously described solution. Before each treatment, patients were assessed with an objective rating scale for dystonia (Burke-Fahn-Marsden scale, severity factors, items for BLS and mouth averaged⁵; this scale was used in the absence of validated rating scales for HFS); efficacy was assessed at the time of the peak effect with the same objective rating scale and the subjective visual analogue scale reported above. Each patient received a single treatment. Latency and duration of the effect were assessed as above.

Results of the trial are reported in table 1. Only two patients rated the efficacy of BTX-B as superior to BTX-A and preferred to continue treatment with BTX-B. The drug was well tolerated, with the most common adverse effect being burning pain during the injection, which was reported by 7 of 11 patients. Other common side effects of BTX-A treatment were negligible.

Comment

This open pilot trial, which is the first to use BTX-B in a neurological condition other than cervical dystonia, suggests that BTX-B is an effective and safe treatment for both BLS and HFS. The time course and magnitude of the improvement observed in our study are similar to those reported in trials with BTX-A for the same conditions, while the duration of the effect appears shorter as the mean duration of effect with BTX-A in these neurological

conditions is 12-16 weeks.⁴ The only peculiar side effect was local pain during the injection, which has not been reported before in trials with BTX-B. This event might be related to the fact that BTX-B is available in a liquid preparation, which has different biochemical properties than the reconstituted solution of BTX-A.²⁻⁴ The severe, adverse reaction reported in a single patient with BLS has not been described in previous trials using this compound for cervical dystonia and has rarely been reported in conjunction with BTX-A use⁶; it should, however, not discourage the planning of further dose ranging studies of BTX-B and studies on larger series of patients designed to compare the effect of BTX-B with both placebo and BTX-A in different neurological disorders.

Competing interests: CC has been reimbursed by Elan, Allergan and Ipsen (manufacturers of different botulinum neurotoxins) for attending several conferences. MFC has been reimbursed by Elan for attending a conference. ARB has been reimbursed by Allergan and Ipsen for attending several conferences.

C Colosimo, M Chianese, M Giovannelli
Dipartimento di Scienze Neurologiche, Università La Sapienza, Rome, Italy

M F Contarino, A R Bentivoglio
Istituto di Neurologia, Università Cattolica del S Cuore, Rome, Italy

Correspondence to: Dr C Colosimo, Dipartimento di Scienze Neurologiche, Università La Sapienza, viale dell'Università 30, I-00185 Rome, Italy; carlo.colosimo@uniroma1.it

References

- 1 **Bentivoglio AR**, Albanese A. Botulinum toxin in motor disorders. *Curr Opin Neurol* 1999;12:447-56.
- 2 **Brashear A**, Lew MF, Dykstra DD, et al. Safety and efficacy of NeuroBloc (botulinum toxin type B) in type A-responsive cervical dystonia. *Neurology* 1999;53:1439-46.
- 3 **Brin MF**, Lew MF, Adler CH, et al. Safety and efficacy of NeuroBloc (botulinum toxin type B) in type A-resistant cervical dystonia. *Neurology* 1999;53:1431-8.
- 4 **Albanese A**, Colosimo C, Carretta D, et al. Botulinum toxin as a treatment for blepharospasm, spasmodic torticollis and hemifacial spasm. *Eur Neurol* 1992;32:112-17.
- 5 **Burke RE**, Fahn S, Marsden CD, et al. Validity and reliability of a rating scale for the primary torsion dystonias. *Neurology* 1985;35:73-7.
- 6 **LeWitt PA**, Trosch RM. Idiosyncratic adverse reactions to intramuscular botulinum toxin type A injection. *Mov Disord* 1997;12:1064-7.

Persistent bitter taste as an initial symptom of amyotrophic lateral sclerosis

Amyotrophic lateral sclerosis (ALS) is characterised by progressive degeneration of upper and lower motor neurones. Clinical symptoms involve weakness, dysphagia, dysarthria,

muscle atrophy and fasciculations, hyper-reflexia, spasticity, Babinski signs, and clonus. Here we report on two patients with sporadic ALS in whom the disease initially presented with a persistent bitter “metallic” taste.

Case reports

Patient 1 was a previously healthy 60 year old woman. Six months before admission, she noticed a persistent bitter taste, dysarthria, and emotional lability. Several weeks later she noticed a progressive weakness in both legs which spread to both arms within four months. At the time of admission, she had bilateral bulbar weakness, episodes of pathological crying, generalised spasticity, muscle atrophy, weakness, and fasciculations. The plantar reflex was extensor on the left side. The remaining neurological examination was unremarkable.

Patient 2 was a previously healthy 64 year old woman. At the time of admission, she reported a four month history of a persistent bitter “metallic” taste confined to the posterior tongue, facial weakness, and clumsiness of the left hand. Neurological examination revealed bilateral bulbar weakness, an increased jaw reflex, slow side to side tongue movement, generalised hyperreflexia, and fasciculations. Spasticity, muscle atrophy, and weakness were predominantly observed in the left arm. The remaining neurological examination was normal.

The patients had not taken prescription or non-prescription drugs during the months preceding the symptoms, or at the initiation of symptoms or at the time of admission. Oral hygiene was good in both cases and xerostomia was not evident. Family history was negative. The occupational and chemical exposure history was unremarkable.

Spatial gustatory function testing with sodium chloride (0.04 and 0.32 M), sucrose (0.07 and 0.32 M), citric acid (0.01 and 0.02 M), and quinine (0.00016 mM) was undertaken. Although both patients described the perception of a bitter taste throughout the examination, the test did not reveal hypogeusia for any quality. In both cases, routine blood chemistry and cerebrospinal fluid studies were normal. Tests for paraneoplastic autoantibodies (Hu, Yo, Ri, Ma, Ta, CV2) were negative. Cranial and spinal magnetic resonance imaging showed mild bilateral atrophy of the precentral gyrus in both patients. Motor evoked potentials revealed slowed central conduction. Peripheral electrophysiological testing showed active denervation, normal nerve conduction, and normal F wave latencies. Thus motor neuropathy with multifocal conduction block, cervical myelopathy, and paraneoplastic motor neurone disease could be excluded. A diagnosis of clinically definite ALS was made, based on the revised El Escorial criteria (<http://www.wfnals.org/articles/elescorial1998.htm>). Treatment with riluzole and α tocopherol was initiated in both patients.

Comment

To our knowledge, dysgeusia has not been described in this disease. The persistent perception of bitter taste developed as an early symptom of the disease in our patients. In this regard, it resembles the dysgeusia known from ciguatera food poisoning, which is thought to produce a bitter taste by blocking sodium channels.¹ However, other sensory symptoms were absent, both clinically and electrophysiologically. The chorda tympani branch of the facial nerve carries taste sensations from the anterior two thirds of the tongue, whereas the glossopharyngeal nerve

and the vagus nerve innervate the posterior third and the epiglottis. It has been shown experimentally and clinically that anaesthesia of the chorda tympani nerve branch results in intensified perception of bitter taste from the posterior tongue, suggesting that input by way of the chorda tympani normally inhibits the glossopharyngeal and vagus nerve input.² In fact, spontaneous bitter taste dysgeusia (phantogeusia) similar to that perceived by our patients was observed in the posterior tongue after anaesthesia of the chorda tympani.² Hence it may be speculated that mild sensory neuropathy of the chorda tympani branches may be responsible for our findings. Sensory signs have indeed been described in ALS. However, if at all, they develop relatively late in the disease.³ Furthermore, the spatial gustatory function test did not reveal hypogeusia confined to a localised region of the tongue in our patients, although the sensitivity of this test for mild gustatory disturbances is probably low.⁴ Unfortunately, neither patient was available for electro-gustometry to further clarify our hypothesis.

Alternatively, the dysgeusia may be of central nervous origin. Both patients presented with bilateral nuclear facial paresis reflecting a prominent bulbar involvement in the disease. Thus it may be speculated that bilateral degeneration of the brain stem solitary tract nucleus may be responsible for the dysgeusia in our patients. Interestingly, dysfunction of the autonomic nervous system—which in part is also regulated by the solitary tract nucleus—has been described in ALS,⁵ supporting the view that this disease may be a multisystem disorder. Thus dysgeusia may indicate brain stem involvement in the disease. As a bulbar onset of ALS is an important predictor of the disease course,⁶ our finding may also be of prognostic value. We cannot provide a definite neuroanatomical basis for our observation, but we believe that future studies may be able to address these issues.

G C Petzold, K M Einhäupl, J M Valdueza

Department of Neurology, Charité Hospital, Humboldt University, Schumannstr 20/21, 10098 Berlin, Germany

Competing interests: none declared

Correspondence to: Dr Petzold; gabor.petzold@charite.de

References

- 1 Pearn J. Neurology of ciguatera. *J Neural Neurosurg Psychiatry* 2001;70:4–8.
- 2 Yanagisawa K, Bartoshuk LM, Catalanotto FA, et al. Anesthesia of the chorda tympani nerve and taste phantoms. *Physiol Behav* 1998;63:329–35.
- 3 Gregory R, Mills K, Donaghy M. Progressive sensory nerve dysfunction in amyotrophic lateral sclerosis: a prospective clinical and neurophysiological study. *J Neural* 1993;240:309–14.
- 4 Smith DV. Assessment of patients with taste and smell disorders. *Acta Otolaryngol Suppl* 1988;458:129–33.
- 5 Beck M, Giess R, Magnus T, et al. Progressive sudomotor dysfunction in amyotrophic lateral sclerosis. *J Neural Neurosurg Psychiatry* 2002;73:68–70.
- 6 Magnus T, Beck M, Giess R, et al. Disease progression in amyotrophic lateral sclerosis: predictors of survival. *Muscle Nerve* 2002;25:709–14.

Schizophrenia and episodic ataxia type 2

The frequent co-occurrence of degenerative cerebellar pathology and schizophrenia, as well as the recently reported increased association rate between autosomal dominant

ataxias and major psychosis, strongly suggests the involvement of the cerebellum in the pathophysiology of schizophrenia.^{1–3} The analysis of associations between psychosis and neurodegenerative diseases may improve our understanding of the pathophysiology of schizophrenia and facilitate the search for susceptibility genes for this disorder.⁴

To our best knowledge, there have been no previous reports about an association between schizophrenia and the periodic autosomal dominant ataxias, such as episodic ataxia type 1 and type 2 (EA1 and EA2). We present a case of a young man who has been diagnosed with paranoid schizophrenia (ICD-10: F20.0) and episodic ataxia type 2.

Case study

The patient, a man aged 27 years, was first admitted to our hospital with psychotic symptoms in June 1995. He presented with paranoid delusions and delusions of reference, acoustic hallucinations (commenting voices), formal thought disorder, and behaviour disorganisation, as well as negative symptoms such as blunted affect, poor rapport, and lack of spontaneity. At this time, he was diagnosed as having paranoid schizophrenia (ICD-10: F20.0) and showed a PANSS (positive and negative symptom scale) total score of 137 (fig 1).

The patient was initially treated with risperidone (6 mg/d) which led to a slight improvement in his psychotic symptoms. After discharge from our hospital in September 1995 he regularly attended our outpatient clinic. Despite treatment with risperidone and later with haloperidol decanoate (20 mg/2 weeks), he continued to have chronic psychotic symptoms, which persisted until re-admission in April 2001. At this admission he was suffering from severe psychosis (paranoid delusions, acoustic hallucinations, formal thought disorder, and behaviour disorganisation) and negative symptoms (fig 1). Antipsychotic treatment with quetiapine (800 mg/d; 4 weeks) and subsequently with amisulpride (600 mg/d; 4 weeks) did not lead to any improvement in the psychosis. At this time, a neurological investigation showed gaze evoked nystagmus and upward gaze palsy, though attacks of ataxia had neither been reported by the patient nor noticed by the nurses.

Because of persistence of the psychotic symptoms, we began treatment with clozapine (400 mg/d) and observed a gradual deterioration in psychosis over the next four weeks despite sufficient serum levels of clozapine. At that time the first severe ataxia attacks appeared. They were manifested by gait ataxia, dysarthria, and slight intention tremor of the upper extremities and persisted for at least several hours. After other causes of cerebellar dysfunction—such as inflammatory, toxic, and vascular disorders—had been excluded, the patient was diagnosed as having episodic ataxia type 2 because he met the following clinical diagnostic criteria: duration of episodes (hours to days), gait and stance ataxia, interictal absence of most symptoms (except oculomotor deficits). Consequently, we began treatment with acetazolamide (200 mg twice daily) and switched the antipsychotic medication from clozapine to zotepine (400 mg/d). This led to both a complete elimination of ataxia episodes and a gradual amelioration of the psychotic symptoms. At the time of discharge six weeks later, the patient's total PANSS score was 90. At all subsequent follow up investigations undertaken monthly until December 2002 the psychiatric symptoms remained unchanged (fig 1) and there was no recurrence of the ataxia attacks.

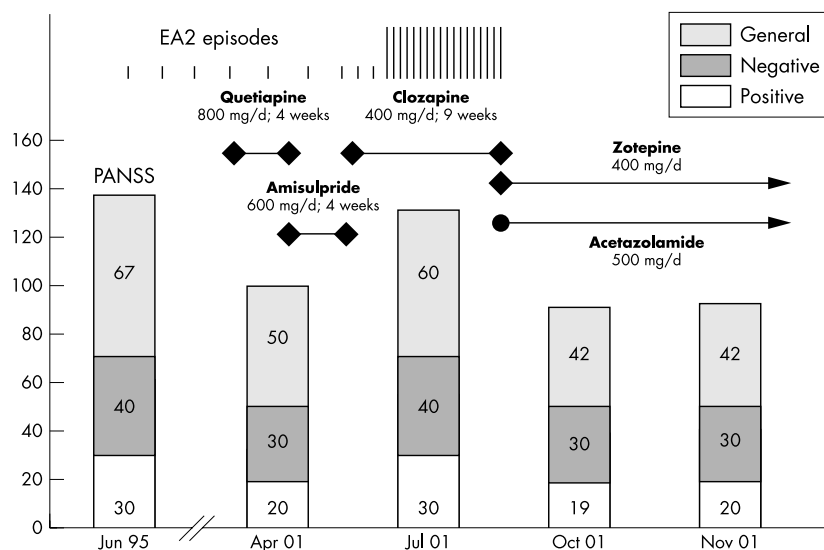


Figure 1 Positive and negative syndrome scale scores, treatment with antipsychotic agents, and the frequency of episodes of ataxia.

Episodic ataxia in this patient obviously follows an autosomal dominant trait. The patient's mother suffers from cerebellar atrophy with severe gait and limb ataxia, dysarthria, and oculomotor deficits. Her father is reported to have had oculomotor deficits as well.

At the age of 12 months, a neurological examination of our patient showed saccadic pursuit and vertical spontaneous nystagmus. Since the age of 18 months, spells of gait and stance ataxia have been described (15 to 20 minutes long, one to four times in four to six weeks). At the age of three years and nine months, a neurological investigation showed gaze evoked nystagmus, saccadic pursuit, and absence of optokinetic nystagmus (both horizontal and vertical). At that age a suspicion of migraine was raised but not confirmed. At the same time abnormal EEG patterns with sharp waves over the left temporal lobe were reported.

Recent EEGs done before, during, and after treatment with clozapine showed abnormal bilateral theta-delta activity (4-7 cps and 2-3 cps) in the temporal and parietal regions. Magnetic resonance (MR) imaging done in 1995, 1997, and 2001 showed no signs of atrophy or cerebral signal alteration. Proton MR spectroscopy done in July 2001 revealed decreased N-acetylaspartate to creatine ratios in the cerebellar vermis region and left cerebellar hemisphere. On ¹²³I-iomazenil SPECT in July 2002, there was a reduced density of the GABA(A)-benzodiazepine receptor complex in the cerebellum as well as in the frontal dorsolateral and occipital regions.

Comment

This case shows an association between clinically diagnosed episodic ataxia type 2 and schizophrenia. Cessation of ataxia episodes as a response to treatment with acetazolamide supports the clinical diagnosis of EA2 and rules out alternative pathologies such as SCA6 and EA1, which are known to have only a partial response to acetazolamide, if any.

Recent association studies have shown that neurodegenerative disorders may predispose to major psychosis.³ SCA6, a disorder of chromosome 19, is not associated with schizophrenia, but patients with SCA8 have shown an increased rate of association with major

psychosis.³ Until now there have been no reports of an association between episodic ataxia and schizophrenia.

Autosomal dominant episodic ataxia type 2 is assumed to be caused by mutations in the gene CACNA1A (chromosome 19p13.1), which encodes the Ca_v2.1 subunit of the voltage gated P/Q calcium channels. As calcium channels are involved in the modulation of neurotransmitter release, it has been hypothesised that they play a role in the pathophysiology of schizophrenia.⁵

Cerebellar atrophy as well as mild cerebellar dysfunction are already known to be associated with schizophrenia. This is the first case of a patient suffering from episodic cerebellar ataxia and schizophrenia, and it points to a possible role of ion channel polymorphism in the pathophysiological mechanisms of schizophrenia.

S Mechtcheriakov, M A Oehl, A Hausmann, W W Fleischhacker

University Clinic of Psychiatry, University Clinic Innsbruck, Anichstrasse 35, A-6020, Innsbruck, Austria

S Boesch

University Clinic of Neurology, Innsbruck

M Schocke

University Clinic of Radiology I, Innsbruck

E Donnemiller

University Clinic of Nuclear Medicine, Innsbruck

Correspondence to: Dr S Mechtcheriakov; s.mechtcheriakov@uibk.ac.at

References

- Martin P, Albers M. Cerebellum and schizophrenia: a selective review. *Schizophr Bull* 1995;21:241-50.
- Jurjus GJ, Weiss KM, Jaskiw GE. Schizophrenia-like psychosis and cerebellar degeneration. *Schizophr Res* 1994;12:183-4.
- Vincent JB, Yuan QP, Schalling M, et al. Long repeat tracts at SCA8 in major psychosis. *Am J Med Genet* 2000;96:873-6.
- Jurewicz I, Owen RJ, O'Donovan MC, et al. Searching for susceptibility genes in schizophrenia. *Eur Neuropsychopharmacol* 2001;11:395-8.
- Dworakowska B, Dolowy K. Ion channels-related diseases. *Acta Biochim Pol* 2000;47:685-703.

Association of cardiomyopathy caused by autonomic nervous system impairment with the Miller Fisher syndrome

We report a case of Miller Fisher syndrome associated with reversible left ventricular wall motion abnormalities similar to takotsubo shaped cardiomyopathy.

Case report

A 58 year old man was admitted to our hospital because of ataxia, ophthalmoplegia, and dysarthria. He had a 10 year history of hypertension. Four weeks before admission, he had common-cold-like symptoms. Ten days before admission, he developed difficulties with walking and speaking. The next day he was unable to walk or lift his eyelids. He was admitted to another hospital, where he was diagnosed as having a brain stem infarct. During admission, he developed tightness in the chest for three to four days which improved spontaneously. Because of exacerbation of his neurological symptoms, he was transferred to our hospital.

On initial physical examination, his blood pressure was 158/106 mm Hg and his heart rate was 108 beats/min and in regular rhythm. He was afebrile and had no respiratory difficulty. On neurological examination, he was fully orientated. His pupils were slightly mydriatic bilaterally (right 6 mm, left 6.5 mm) and the light reflex was absent on both sides. Complete ophthalmoplegia and peripheral facial palsy were observed bilaterally. He had severe dysarthria with restricted movements of the soft palate and tongue. Although muscle strength was preserved, deep tendon reflexes were absent in the four extremities. The plantar responses were flexor. There was no definite involvement of sensory disturbance. Ataxia was observed in the four extremities.

Routine laboratory tests were normal except for a slightly increased white blood cell count. Cerebrospinal fluid obtained on the first hospital day showed one monocyte per high power field and an increased protein level of 82 mg/dl. Aetiological investigations, including anti-GM1, anti-GM2, anti-GD1a, anti-GM1b, anti-GT1a, anti-GQ1b, anti-GD1b, anti-GT1b titres, were all negative. Results of thyroid function tests, angiotensin converting enzyme level, c-ANCA, p-ANCA, anti-acetylcholine receptor antibody, serum electroimmunophoresis, and polymerase chain reaction analysis for CSF tuberculosis and herpes simplex virus were all normal. Serum titres of influenza A and B, measles, mumps, varicella-zoster virus, cytomegalovirus, Epstein-Barr virus, herpes simplex virus, rubella, and mycoplasma were also normal. Cranial magnetic resonance (MR) imaging and MR angiography showed no abnormal lesions. EEG findings were normal. Nerve conduction studies showed decreased F wave persistence in the arms. Motor and sensory nerve conduction velocities were well maintained.

On the basis of the neurological findings, we established a diagnosis of the Miller Fisher syndrome. The patient was treated with a 12 litre plasma exchange over six days, followed by high dose intravenous gamma globulin (400 mg/kg/day for five continuous days).

There was no chest pain during admission to our hospital; however, an ECG on the first hospital day showed sinus tachycardia with slightly elevated ST segments in leads V3-V5. T waves were inverted in leads I, II, aVL, and V3-6 on the fifth day. These findings, in




Figure 1 MIBG (metaiodobenzylguanidine) myocardial scintigrams on the 12th day (A) and the 70th day (B). On the 12th day, MIBG uptake was reduced in the anterior, inferior, and lateral walls (A). The uptake had recovered by the 70th day (B).

conjunction with the previous episode of chest tightness, led us to suspect acute coronary syndrome, and we undertook coronary angiography. Although the coronary arteries were free of any lesions, a left ventriculogram showed severe hypokinesis in the antero-lateral, apical, and diaphragmatic segments, with an ejection fraction of 34%. Provocative vasospasm was not confirmed. Maximum creatine kinase MB release was 8.0 ng/ml (normal < 5.0 ng/ml). A left ventriculogram on the 13th hospital day showed an improvement in the hypokinesis, with an ejection fraction of 44%. There were no specific abnormal findings on myocardial biopsy. Serum noradrenaline (norepinephrine) concentrations were increased to 810 ng/l, 1160 ng/l, and 549 ng/l on the seventh, 14th, and 78th day, respectively (normal 90–420 ng/l). Thallium-201 scintigraphy on the ninth day showed only mild hypoperfusion in the lateral wall; however, 123 I-metaiodobenzylguanidine (MIBG) scintigraphy done on the 12th day revealed a decrease in uptake in the anterior, inferior, and lateral walls in the early phase (fig 1A). MIBG scintigraphy on the 70th day showed improved uptake (fig 1B). The patient was discharged on the 130th day with marked improvement in both ophthalmoplegia and gait disturbance.

Comment

In this case, serum anti-GQ1b antibody was negative despite its common association with Miller Fisher syndrome. However, we feel that the triad of ataxia, areflexia, and ophthalmoplegia in association with dissociation of protein and cytological findings in the CSF and the absence of specific findings on cranial MR imaging and MR angiography is sufficient to justify our diagnosis of the Miller Fisher syndrome. Autonomic dysfunctions consisting of sinus tachycardia, increased serum noradrenaline, and decreased MIBG uptake were noted in this case. As these dysfunctions were reversible and paralleled the severity of the Miller Fisher syndrome, they probably have the same aetiology. Because 123 I-metaiodobenzylguanidine is a physiological

analogue of noradrenaline, and is actively transported into the noradrenaline granules of sympathetic nerve terminals by uptake-1, decreased MIBG uptake in the early phase suggested the involvement of cardiac autonomic nerves. Normal findings on coronary angiography, as well as unremarkable findings on thallium-201 scintigraphy, ruled out ischaemic cardiomyopathy. Thus autonomic dysfunction in the cardiovascular system was considered to have been an important factor in the present case.

Takotsubo shaped cardiomyopathy is a unique heart syndrome characterised by reversible left ventricular apical wall motion abnormalities with chest symptoms, ECG changes, and minimal myocardial enzymatic release mimicking acute myocardial infarction without coronary stenosis.^{1,2} The syndrome is named "takotsubo shaped" cardiomyopathy as it has often been reported in Japan and the unique configuration of left ventriculogram resembles a takotsubo, a Japanese word describing an octopus pot.² The left ventricular wall motion abnormality observed in the present case can be included in the takotsubo shaped cardiomyopathy category because of its reversible course and other clinical characteristics. Although the detailed aetiology of this syndrome remains unclear, enhanced sympathetic activity or vasospasm are considered to play a role in the development of contraction abnormalities.¹ Three cases of Guillain-Barré syndrome with reversible left ventricular dysfunction have previously been reported.^{3,5} In all these cases, the apical regions were mainly involved. In two of the three cases, MIBG scintigraphy was done and showed decreased uptake around the apex in both cases.^{3,4}

To our knowledge, this is the first report of a case of Miller Fisher syndrome with reversible cardiomyopathy caused by impairment of the autonomic nervous system. This cardiac syndrome may easily be missed because of its transient nature, with minimal abnormalities on routine laboratory findings. However, careful cardiac examination including ECG, left

ventriculography, and MIBG scintigraphy may lead to the identification of further cases of Miller Fisher syndrome showing this cardiac complication.

M Oomura, T Yamawaki, H Oe, H Moriwaki, K Miyashita, H Naritomi

Cerebrovascular Division, Department of Internal Medicine, National Cardiovascular Centre, 5-7-1 Fujishirodai, Suita, Osaka 565-8565, Japan

Y Yasumura

Cardiovascular Division, Department of Internal Medicine, National Cardiovascular Centre

Correspondence to: Dr Hiroaki Naritomi; hnaritomi@hsp.ncvc.go.jp

References

- 1 Tsuchihashi K, Ueshima K, Uchida T, *et al.* Transient left ventricular apical ballooning without coronary artery stenosis: a novel heart syndrome mimicking acute myocardial infarction. *J Am Coll Cardiol* 2001;**38**:11–18.
- 2 Dote K, Sato H, Tateishi H, *et al.* Myocardial stunning due to simultaneous multivessel spasms: a review of five cases. *J Cardiol* 1991;**21**:203–14.
- 3 Iga K, Himura Y, Izumi C, *et al.* Reversible left ventricular dysfunction associated with Guillain-Barré syndrome – an expression of catecholamine cardiotoxicity? *Jpn Circ J* 1995;**59**:236–40.
- 4 Yoshii F, Kozuma R, Haida M, *et al.* Giant negative T waves in Guillain-Barré syndrome. *Acta Neurol Scand* 2000;**101**:212–15.
- 5 Bernstein R, Mayer SA, Magnano A. Neurogenic stunned myocardium in Guillain-Barré syndrome. *Neurology* 2000;**54**:759–62.

No evidence of type 1 or type 3 hypersensitivity mechanism in amoxicillin/clavulanic acid induced aseptic meningitis

Drug induced aseptic meningitis has been reported in response to various agents, in particular non-steroidal anti-inflammatory drugs, intravenous immunoglobulins, anti-CD3 monoclonal antibody (OKT3), and antibiotics.¹ Hypersensitivity reactions (especially type 1 and type 3) have been invoked as the cause by many investigators.¹ This hypothesis is supported by the detection of immune complexes in the serum or cerebrospinal fluid (CSF) of some patients.¹

To our knowledge, only two cases of aseptic meningitis induced by amoxicillin with or without clavulanic acid have been reported.^{2,3} We report a third case of probable amoxicillin induced aseptic meningitis where we performed laboratory studies for type 1 or type 3 hypersensitivity mechanisms.

Case report

A 62 year old man presented to our hospital because of fever (up to 40°C) and severe headache for four days. Both had begun approximately six hours after the intake of one tablet of 500 mg amoxicillin plus 125 mg clavulanic acid (Augmentan®, SmithKline Beecham) as antibiotic prophylaxis before a planned dental surgical procedure. He had discontinued the antibiotic after two tablets and cancelled the appointment with the dentist. Five weeks before, he had already had to cancel the planned operation, because he had exactly the same (but more severe) signs and symptoms, also approximately six hours after the intake of one tablet of amoxicillin/clavulanic acid. Following discontinuation of the prophylactic antibiotic (after two tablets), the fever and headache had subsided over the course of three weeks without any treatment.

Tests were not performed during that episode. He could not remember having taken amoxicillin/clavulanic acid before that first occasion. He did not report any accompanying "allergic" signs, such as facial oedema, conjunctivitis, or rash during either of the two episodes, and he had no previous history of allergy or connective tissue disorder.

His neurological status was unremarkable, and in particular there was no neck stiffness. His physical status was also normal except for a body temperature of 38.2°C. Cranial computed tomography revealed no abnormalities. CSF examination showed the following results: leucocyte count 54 cells/ μ l (82% lymphocytes, 12% monocytes, 4% lymphoid cells, 2% granulocytes); glucose 62 mg/dl (serum 98 mg/dl); protein 94 mg/dl; Q_{alb} 13.4 (1000 \times CSF albumin/serum albumin, normal < 7.4); IgG index 9.38 (1000 \times CSF IgG/serum IgG); oligoclonal bands negative. Bacterial and fungal cultures from CSF were negative. Blood analyses were also normal except for a slightly raised C reactive protein (1.1 mg/dl, normal < 0.5 mg/dl). Additional investigations did not support an underlying type 1 or type 3 hypersensitivity mechanism, as no specific IgE to amoxicillin (< 0.35 IU/ml) or immune complexes interacting with C1q (< 20 IE/ml) were detected in his serum or CSF. Without further treatment, he recovered completely within one week.

Comment

On the basis of the history and findings (two identical episodes of high fever and headache shortly after intake of the prophylactic antibiotic, and sterile CSF pleocytosis at least during the second episode), we diagnosed probable amoxicillin/clavulanic acid induced aseptic meningitis. However, we could not find any evidence suggesting an underlying type 1 or type 3 hypersensitivity reaction. Further studies are therefore warranted.

S Kastenbauer, H-W Pfister

Department of Neurology, Klinikum Großhadern, Ludwig-Maximilians University, Marchioninstr 15, 81377 Munich, Germany

M Wick

Department of Clinical Chemistry, Klinikum Großhadern

Correspondence to: Dr Kastenbauer; stefan@kastenbauer.de

References

- 1 **Moris G**, Garcia-Monco JC. The challenge of drug-induced aseptic meningitis. *Arch Intern Med* 1999;159:1185-94.
- 2 **Czerwenka W**, Gruenwald C, Conen D. Aseptic meningitis after treatment with amoxicillin. *BMJ* 1999;318:1521.
- 3 **Wittmann A**, Wooten GF. Amoxicillin-induced aseptic meningitis. *Neurology* 2001;57:1734.

Another adverse effect of aspirin: bilateral vestibulopathy

Widely used for more than 2000 years, salicylic acid has numerous beneficial effects. It may also lead to several adverse reactions,

affecting for instance the auditory system.¹ Persistent dysfunction of the vestibular system, however, has not yet been described. We report a patient who took 5-6 g aspirin a day for three days for arthralgia. Subsequently he felt unsteady and had oscillopsia while walking, but no tinnitus or hypacusis. Caloric irrigation revealed a bilateral vestibulopathy which was most probably caused by the direct effect of aspirin on the vestibular hair cells.

Case report

A 61 year old teacher took 5-6 g aspirin a day for three days to treat his arthralgia, but no other drugs during this period. Two or three days later he felt unsteady while walking. This problem was worse on uneven ground and in the dark. During head movements and while walking he perceived apparent motion of the visual scene and his vision was blurred. Hearing was normal and he did not complain of tinnitus. He had not had vertigo or hearing problems previously, and his family history was also unremarkable. Though he had had monoclonal (IgG lambda) gammopathy for five years, a bone marrow biopsy proved normal, and thus his condition had been diagnosed as "monoclonal gammopathy of unknown significance."

As all his symptoms persisted, he came to our dizziness unit nine months later. The Halmagyi-Curthoys test (head impulse test to evaluate the function of the semicircular canals) was pathological and revealed a dynamic deficit of the horizontal semicircular canal bilaterally. Romberg testing showed increased sway which worsened when the eyes were closed. His gait was broad based and also worsened with the eyes closed. However, his hearing was normal, and he had no cerebellar signs.

Electronystagmography revealed a significant bilateral caloric hyporesponsiveness (peak slow-phase velocity of the caloric nystagmus during irrigation with 44°C warm water: right ear, 2°/s; left ear, 5°/s; and with 30°C cold water: right ear, 5°/s; left ear, 5°/s). Further, the pre- and postrotatory nystagmus lasted less than three seconds and showed a gain of < 0.2. Hearing tests, including an audiogram, were normal. Blood tests for other possible causes of bilateral vestibulopathy (antibodies against inner ear structures, antinuclear antibodies, anticytoplasmic antibodies, rheumatic factor, vitamin B-12, folic acid, and so on²), as well as high resolution magnetic resonance imaging of the cerebello-pontine angle and labyrinth were normal. As mentioned above, testing of the serum revealed the presence of monoclonal IgG-lambda gammopathy (total protein 8.7 g/dl (normal range 6.0 to 8.0 g/dl); IgG concentration 28.2 g/l (normal range 7.0 to 16.0 g/l)).

Comment

Pathophysiologically, the patient's complaints are fully explained by bilateral vestibulopathy: the oscillopsia is caused by a defect of the vestibulo-ocular reflex, and the unsteadiness by a defect of the vestibulospinal reflexes, especially in darkness when vision cannot substitute for absent vestibular function. The

time course of symptom development following the ingestion of a high dose of aspirin provides strong evidence that the isolated and persistent bilateral vestibulopathy was caused by the drug. Although aspirin induced bilateral vestibulopathy has not been reported before, it is likely that other patients taking aspirin have developed it, as bilateral vestibulopathy is often overlooked.

For more than 150 years it has been known that high doses of salicylates can cause tinnitus, loss of absolute acoustic sensitivity, and alterations of perceived sounds, which may develop in the initial days of treatment.¹ It is also known that the susceptibility of individual subjects to salicylate induced inner ear toxicity varies greatly, but why this is so is unclear. Various attempts have been made to explain the toxic effects of salicylic acid. Otoacoustic emissions have been used to show that salicylates cause changes in the mechanosensory functioning of the cochlea; in particular, spontaneous emissions are decreased.³ Histopathological animal studies have revealed significant changes of only the outer hair cell lateral membrane. In vitro experiments have shown that the fast motile responses of outer hair cells are reduced. As regards the underlying mechanisms, aspirin seems to directly inhibit the mechano-electrical transduction process by partitioning the salicylate molecules in the membrane of hair cells.^{4,5} These latter findings suggest to us that this newly described adverse reaction to aspirin may be related to our patient's monoclonal IgG-lambda gammopathy. The raised IgG concentration could have promoted such partitioning of the molecules in the hair cell membrane, assuming they are able to enter the endolymphatic space. However, this does not explain the isolated impairment of the vestibular function.

From a clinical point of view, it is relevant to consider this additional adverse effect of aspirin, especially as it is unpredictable owing to varying individual susceptibilities. If a patient has taken higher dosages of aspirin and complains of dizziness, his vestibular function should be tested for bilateral vestibulopathy.

M Strupp, K Jahn, T Brandt

Department of Neurology, Klinikum Grosshadern, Marchioninstrasse 15, Ludwig-Maximilians University, 81377 Munich, Germany

Correspondence to: Dr Michael Strupp; mstrupp@nef.med.uni-muenchen.de

References

- 1 **Cazals Y**. Auditory sensorineural alterations induced by salicylate. *Prog Neurobiol* 2000;62:583-631.
- 2 **Brandt T**. *Vertigo: its multisensory syndromes*, 2nd ed. London: Springer, 1999.
- 3 **Quaranta A**, Portolatti P, Camporeale M, et al. Effects of salicylates on evoked otoacoustic emissions and remote masking in humans. *Audiology* 1999;38:174-9.
- 4 **Tunstall MJ**, Gale JE, Ashmore JF. Action of salicylate on membrane capacitance of outer hair cells from the guinea-pig cochlea. *J Physiol (Lond)* 1995;485:739-52.
- 5 **Kakehata S**, Santos-Sacchi J. Effects of salicylate and lanthanides on outer hair cell motility and associated gating charge. *J Neurosci* 1996;16:4881-9.